



***PMB Definition Guidelines for Hepatocellular Carcinoma***

**Disclaimer:**

***The hepatocellular carcinoma benefit definition has been developed for the majority of standard patients. These benefits may not be sufficient for outlier patients. Therefore regulation 15h and 15l may be applied for patients who are inadequately managed by the stated benefits. The procedure codes are just an indication of applicable procedure codes, however some significant procedure codes may not have been included. The benefit definition does not describe specific in-hospital management such as theatre, anaesthetists, anesthetic drugs, supportive medication and nursing care. However, these interventions form part of care and are prescribed minimum benefits.***

## Table of Contents

1. Introduction .....	5
2. Scope and Purpose.....	5
3. Background of hepatocellular carcinoma.....	6
4. Epidemiology.....	7
5. Pre-diagnostic work up of patients with suspected hepatocellular carcinoma.....	7
6. Diagnosis of hepatocellular carcinoma.....	8
7. Staging and Risk Assessment of Hepatocellular carcinoma.....	11
8. Treatment options for HCC .....	12
8.1. Curative Treatments.....	12
8.2. Palliative Therapies.....	13
8.3. Treatment Algorithms.....	14
9. Follow up after surgical resection.....	17
10. References.....	19

## **Abbreviations**

AASLD	American Association for the Study of Liver Diseases
AFP	Alpha fetoprotein
BCLC	Barcelona Clinic Liver Cancer
CLIP	Cancer of the Liver Italian Program
CMS	Council for Medical Schemes
CT	Computed tomography
CTP	Childs-Turcotte-Pugh score
DNs	Dysplastic nodules
DTPs	Diagnosis treatment pairs
EBRT	External Beam Radiation
EPI	Expanded Program of Immunization
FBC	Full Blood Count
HBV	Hepatitis B virus
HCC	Hepatocellular carcinoma
HCV	Hepatitis C virus
INR	International normalized ratio
LFTs	Liver function tests
LRT	Loco-regional treatments
LT	Liver transplantation
MCT	Microwave coagulation therapy
MRI	Magnetic resonance imaging
PEI	Percutaneous ethanol injection
PMB	Prescribed Minimum Benefits
RCT	Randomized controlled trials
RFA	Radiofrequency ablation
SBRT	Stereotactic body radiation therapy
SHARP	Sorafenib Hepatocellular Carcinoma Assessment Randomized Protocol
TACE	Transarterial chemoembolization
WHO	World Health Organization

## 1. Introduction

1.1. The legislation governing the provision of the Prescribed Minimum Benefits (PMBs) is contained in the Regulations enacted under the Medical Schemes Act, No. 131 of 1998 (the Act). In respect of some of the Diagnosis Treatment Pairs (DTPs), medical scheme beneficiaries find it difficult to know their entitlements in advance. In addition, medical schemes interpret these benefits differently, resulting in a lack of uniformity of benefit entitlements.

1.2. The benefit definition project is coordinated by the Council for Medical Schemes (CMS) and aims to define the PMB package, as well as to guide the interpretation of the PMB provisions by relevant stakeholders.

## 2. Scope and Purpose

2.1. The guidelines are intended as a recommendation for the diagnosis, treatment and care of individuals with early and advanced stage hepatocellular carcinoma in any clinically appropriate setting as outlined in the Act.

2.2. The purpose is to provide detailed clarification in respect of benefit and entitlements to members and beneficiaries of medical schemes.

**Table 1: Possible ICD10 codes for identifying hepatocellular carcinoma**

ICD 10 code	WHO description
C22.0	Malignant neoplasm, liver cell carcinoma
C22.9	Malignant neoplasm, liver, unspecified

2.3. The CMS acknowledges that some patients will not qualify for PMB entitlements under the definition of treatable cancers as outlined in explanatory note 3, annexure A of the Act. In these instances, when the treatment intent is no longer curative, DTP 260S, may be applied depending on the clinical case.

**Table 2: Applicable PMB code in hepatocellular cancer**

PMB Code	PMB Description		ICD10 Code	ICD10 Description
260S	# Imminent death regardless of diagnosis	# Comfort care; pain relief; hydration	Z51.5	Palliative care

### **3. Background on hepatocellular carcinoma**

- 3.1. Hepatocellular carcinoma (HCC) is a primary malignancy of the liver and occurs predominantly in patients with underlying chronic liver diseases and cirrhosis. Induced by multiple etiologies, HCC has a complex pathogenesis. Most causes of HCC causes liver injury through the development of liver inflammation and fibrosis. This eventually results in the disordered liver cytoarchitecture characteristic of liver cirrhosis.
- 3.2. The disease processes, which result in malignant transformation, occur through a variety of pathways, many of which may be modified by external and environmental factors, and eventually lead to genetic changes that delay apoptosis (programmed cell death) and increase cellular proliferation.
- 3.3. HCC typically forms soft masses with foci of hemorrhage or necrosis ranging in size from less than 1 to over 30 cm. The cirrhotic liver exhibits focal areas of abnormal, immature hepatocytes and as such, dysplastic foci (<1 mm) or dysplastic nodules (DNs) ( $\geq 1$  mm) arising in the background of cirrhosis which are considered precancerous lesions.
- 3.4. Small HCC, with a maximum diameter of less than 2cm, have been subdivided into vaguely nodular (early HCC) and distinctly nodular HCC (progressed HCC) on the basis of the presence of atypia and other morphologic features (Hytirogou, Park & Krinsky, 2007).
- 3.5. Although both the low and high grade nodules have a potential to develop into HCC, high grade dysplastic nodules pose a much higher risk (Park, 2011; Kobayashi, Ikeda & Hosaka, 2006). Furthermore, as differentiating DN's, especially high-grade DN's, from early HCC can be challenging, the distinction is made based on recommendations of International Consensus Guidelines (The International Consensus Group for Hepatocellular Neoplasia, 2009) which states that the presence of stromal invasion is considered to be the hallmark feature that differentiates early HCC from DN's. The two patterns reflect differing long-term clinical outcomes (The International Consensus Group for Hepatocellular Neoplasia, 2009).
- 3.6. The growth of the HCC dysplastic nodules typically occurs in an asymptomatic phase which may develop over a number of years. The estimated doubling times varies between one and 19 months, with a median of six months (Sheu, Sung & Chen, 1985; Barbara, Benzi & Galani, 1992).

#### **4. Epidemiology**

- 4.1. HCC represents more than 90% of primary liver cancers. Hepatocellular Carcinoma (HCC) is the 6<sup>th</sup> most common cancer in the world and the third cause of cancer related death accounting for 7% of all cancers (Kew, 2014; Raoul, 2008).
- 4.2. The prevalence of HCC worldwide parallels that of viral hepatitis and the majority of cases are associated with Hepatitis B virus (HBV) and Hepatitis C virus (HCV). Worldwide, approximately 54% of HCC cases can be attributed to HBV infection, while 31% are attributed to HCV infection, leaving approximately 15% associated with other causes (Parkin, Bray, Ferlay & Pisani, 2002; Borsh, Ribes & Diaz, 2004).
- 4.3. An estimated 65 million people in Africa are chronically infected with hepatitis B virus (HBV), with 2.5 million of them in South Africa (Burnett, Kramvis, Dochez & Meheus, 2012).
- 4.4. In South Africa, the incidence of liver cancer is ranked at number 14 and it is the 7<sup>th</sup> leading cause of death amongst the cancers (Global Burden of Disease Cancer Collaboration, 2016).
- 4.5. Cirrhosis, which may be caused by chronic viral hepatitis, alcohol and inherited metabolic diseases, is also an important risk factor for HCC. HCC is a significant cause of cancer mortality in sub-Saharan Africa, and 46 000 new cases are diagnosed annually (Parkin, Ferlay & Hamdi-Cherif, 2003).
- 4.6. The age-standardized incidence of HCC is as high as 41.2/100 000 persons/year, with prognosis being poor and 92% dying within 1 year of the onset of symptoms (Kew, 2013). Given that the HBV DNA incorporates itself into the host hepatocyte genome, those with occult hepatitis B virus infection (i.e. HBsAg-negative with detectable serum HBV DNA), or those with previous exposure, are still at risk of HCC (Kew, Welschinger & Viana, 2008).
- 4.7. The worldwide burden of HCC is thought likely to continue and whilst significant progress has been made worldwide, including in South Africa through the introduction of the HBV vaccine in the Expanded Program of Immunization (EPI), the prevalence of chronic liver disease is expected to remain significant among the older population, which is at risk of developing HCC.

#### **5. Pre-diagnostic work up of patients with suspected hepatocellular carcinoma**

- 5.1. With reported sensitivity and specificity of 60% and 97% respectively, ultrasound of the whole abdomen is recommended as PMB level of care during pre-diagnosis. If the patient is known to have pre-existing

cirrhosis and the mass is greater than 2 cm in diameter, there is a greater than 95% chance that the lesion is a HCC (Arguedas, 2003).

- 5.2. A raised serum alpha fetoprotein (AFP) of > 400 ng/ml, confirms the diagnosis and further investigations including imaging studies, are required to establish the most appropriate therapy. AFP is principally the result of production by the tumour or by regenerating hepatocytes, and its elevation has also been recognized in the presence of acute and chronic viral hepatitis – notably seroconversion following hepatitis B infection, as well as in patterns with cirrhosis caused by hepatitis C.
- 5.3. AFP is often elevated in hepatocellular carcinoma and may be useful in the diagnosis and follow-up of cases of hepatocellular carcinoma and as such, along with ultrasound, it is the current gold standard and most commonly used biomarker for patients at risk for HCC (Peng, Chen, Lai, Jeng, Sheu & Hsu, 2004). Although serum AFP levels of more than 400ng/ml are considered diagnostic, such high values are observed only in small percentage of patients with HCC (Colombo, 2001).
- 5.4. Despite its low cost, AFP is also only 40-64% sensitive because many tumours do not produce AFP at all, or do so only at a very advanced stage. AFP levels can therefore be subject to misinterpretation. When elevated, AFP is 75-91% specific and values greater than 400 ng/ml are generally considered diagnostic of HCC in the proper clinical context, including appropriate radiologic findings.
- 5.5. Studies suggest that in patients thought to have hepatocellular carcinoma on clinical grounds, AFP levels > 400 ng/ml should strongly conform the presence of hepatocellular carcinoma by tissue diagnosis (Johnson, 2001). In cases where the AFP is normal, further radiological imaging (CT, MRI, or lipiodol angiography with follow up CT) should follow to allow for a more accurate diagnosis to be made, and to proceed to the assessment of treatment without the need for biopsy. In the few cases where real diagnostic doubt persists, biopsy may be indicated (Doyle & Sherman, 2017; Finn, 2016).

## **6. *Diagnosis of hepatocellular carcinoma***

- 6.1. Laboratory evaluation of patients with newly diagnosed hepatocellular carcinoma (HCC) should include testing to determine the severity of the underlying liver disease, as well as elucidating the etiology of the underlying disease.
- 6.2. A computed tomography (CT) of the chest, abdomen and pelvis or magnetic resonance (MR) imaging is required for intrahepatic staging of HCC. A CT scan is considered preferred technique for staging as it provides reliable detection of both intrahepatic and extrahepatic spread of the tumour. American Association for the Study of Liver Diseases (AASLD) guidelines have proposed that a single modality

CT or MRI is sufficient when radiologic hallmark features are present in a nodule more than 1 cm, and that a second modality is needed when atypical features are present (Bruix & Sherman, 2011).

6.3. Whilst the decision to biopsy a lesion suspected of being hepatocellular carcinoma is the subject of ongoing controversy, it is currently accepted that imaging techniques may confidently establish the diagnosis, without the need for biopsy confirmation, in HCCs larger than 2 cm. Biopsy, however, can still be recommended in lesions between 1 -2 cm, but a negative response cannot be used to completely rule out malignancy (Lencioni, Cioni & Bartolozzi, 2005).

6.4. Once a patient has been diagnosed with HCC, treatment staging and treatment options will influence the treatment workup. Evaluation should be based on hepatitis B panel, hepatitis C, renal panel, liver function tests, and measurement of prothrombin time expressed as international normalized ratio (INR), albumin and platelet count, complete full blood count, measurement of serum AFP.

**Table 3: Pre-diagnosis, diagnosis and staging work-up for hepatocellular cancer**

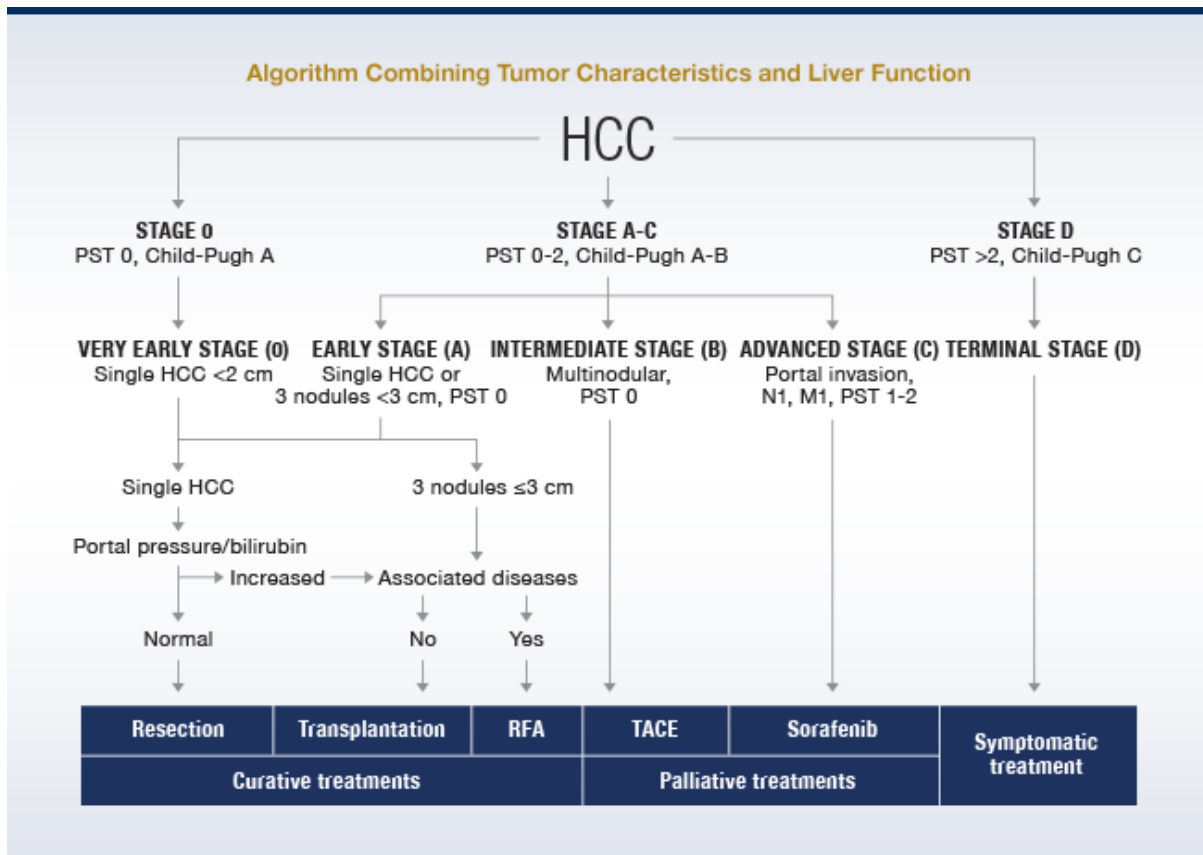
Description		Frequency	Comments (where necessary)
<b>Consultations</b>	GP	1	
	Physician/ Gastroenterologist/ Surgeon	2	GP should refer the patient
	Oncologist: Medical or radiation	2	Motivation required for more consultations
	Anesthesiologist	1	To determine fitness for surgery
<b>Imaging radiology</b>	Chest x-ray	1	
	Ultrasound study of whole abdomen incl. pelvis	1	If inconclusive a second ultrasound may be required upon specialist motivation
	CT chest, abdomen and pelvis	1	
	MRI liver with contrast	1	Only if potentially resectable
	Diagnostic gallium scans	1	On motivation. Gallium may help distinguish regenerating nodules of cirrhosis from HCC. Only for operable patients. Not routine.
	Bone scan	1	On motivation, when clinically indicated.

<b>Imaging procedures</b>	Ultrasound Doppler (hepatic & splenic veins & inferior vena cava in assessment of portal venous hypertension)	1	intraoperative ultrasound with or without vascular assessment pre-surgery
<b>Histopathology</b>	Liver biopsy	1	For advanced disease. The approach will be determined on an individual basis. Not warranted if definitive CT and AFP>400.
	Histology per sample/ blocks/ frozen sections/	1	
	Immunohistochemistry	1	
<b>Laboratory investigations</b>	Alpha-feto protein (AFP)	1	Levels higher than 400 ng/mL are considered diagnostic with appropriate imaging studies
	Liver function test (LFT)	1	Elevated liver enzymes reflect active hepatitis due to viral infection, current alcohol use, or other causes  Increased bilirubin level usually indicates advanced liver disease
	Full blood count (FBC) including platelets	1	Anaemia haemoglobin may be related to bleeding from varices or other sources
	INR	1	
	U&E and Creatinine	1	Increased serum creatinine level may reflect intrinsic renal disease or hepatorenal syndrome
	Hepatitis B surface antigen (HBsAg) and anti-HCV (HBcAb)		If not done already in earlier investigations
	Calcium	1	Hypercalcemia - Ectopic parathyroid hormone production is possible in 5-10% of patients with HCC
	Glucose	1	Hypoglycaemia may represent end-stage liver disease
	Cholesterol	1	High cholesterol levels are often raised in HCC

*Please note: Patients with co-morbid diseases impacting on the treatment pathways might require additional consultations, radiology and lab tests.*

## **7. Staging and Risk Assessment of Hepatocellular carcinoma**

- 7.1. The prognosis of HCC is a reflection of both tumour characteristics (i.e. size, location, tumour biology) and the degree of underlying liver disease. A number of systems have been proposed to predict the prognosis for hepatocellular carcinoma (HCC), incorporating important determinants of survival such as the severity of underlying liver disease, the size of the tumour, extension of the tumour into adjacent structures, and the presence of metastases (Clip Investigators, 2000; Lai, Lam & Wong, 1981).
  
- 7.2. The most commonly used systems are the tumour, node, metastasis (TNM), Barcelona Clinic Liver Cancer (BCLC) systems and the Cancer of the Liver Italian Program (CLIP) score. The BCLC which takes into account total cancer load, the stage of the cirrhosis, and the patient's functional status, with the goal of determining expected survival, as well as proposing possible treatment, appears to have the highest acceptance (Grieco, Pompili, Caminiti, Miele, Covino & Alfei, 2005). The BCLC classification divides HCC patients in 5 stages 0, A, B, C and D according to pre-established prognostic variables and allocates therapies according to treatment related status. The fact that it has been externally validated and that it provides a connection between the stages and the different treatment modalities serves to increase its popularity (Llovet, Fuster & Bruix, 2004).
  
- 7.3. The Childs-Turcotte-Pugh score (CTP) score is the most widely used grading system for liver function in cirrhotic patients. Although the CTP score by itself does not include any HCC-specific parameters, it has been incorporated into multiple contemporary scoring systems including the Barcelona Clinic Liver Cancer (BCLC) as shown below:



PST=performance status test; N=lymph node; M=metastasis; RFA=radiofrequency ablation; TACE=transarterial chemoembolization.

## 8. Treatment options for HCC

### 8.1. Curative Treatments

The only definitive treatment modalities capable of achieving a cure are hepatic resection, hepatic transplantation and percutaneous ablation (Bruix & Sherman, 2011). To date, it is estimated that up to 30% of cases can be considered for treatment with a curative intent (Llovet, Bisceglie, Bruix, Kramer, Lencioni & Zhu, 2008). Loco-regional treatments (LRT) play a key role in the management of HCC and the goal of LRT is the down staging of the tumour as well as assisting in maintaining the patient on the transplant list during the waiting period should the tumour grow in size.

#### 8.1.1. Hepatic resection

Hepatic resection is considered the surgical procedure of choice for Child Pugh A patients with solitary tumour confined to the liver without radiographic evidence of invasion of the vasculature and preserved liver function (Wong & Frenette, 2011; Ishizawa, Hasegawa, Aoki, Takahashi, Inoue, Sano & Imamura, 2008).

The 1-, 3-, and 5-year overall survival rates of selected patients who had hepatic resection were 89.0%, 64.3%, and 53.0 %, respectively (Liu, Wang, Bao, Sun & Xing, 2016). Although surgical resection gives the best chance for cure of HCC, only 10% to 30% of patients at diagnosis are eligible for surgical interventions (Lau & Lai, 2007). Additionally, the risk of post-resection tumour occurrence has a bearing on the decision to pursue local resection due to the fact that following liver resection, as many as 75% of patients will develop intrahepatic recurrence within 5 years (Mancuso, 2013). In patients with liver cirrhosis, surgical resection is limited due to the risk of inducing postoperative liver failure.

### **8.1.2. Liver Transplantation**

Liver transplantation (LT) is considered in patients with 3 nodules less than 3 cm or with single tumors less than 5 cm, with liver function impairment precluding resection. It is one of the options of curative care for those patients with HCC that are not eligible for liver resections. It eliminates the possibility of local recurrence at the resection margin and, moreover, removes the cirrhotic liver, which is clearly predisposed to tumour formation (Busutti, Farmer & Yersiz, 2005; Roberts, Angus & Bryce, 2004).

### **8.1.3. Ablative Therapies**

Radiofrequency ablation (RFA), microwave coagulation therapy (MCT) and percutaneous ethanol injection (PEI) are the three most commonly used local ablative treatment modalities for treatment of small primary HCC, and are considered the best treatment option for patients with early stage HCC who are not suitable for resection or transplantation. RFA is minimally invasive and has a reported 3-year survival rate averaging above 60% and the 5-year overall survival rate ranging from 18% to 51.6% in randomised controlled trials (Chen, Li & Zheng, 2006; Camma, Di Marco & Orlando, 2005). Long term studies indicate that Child–Pugh A patients with successful tumour necrosis may achieve a 50% survival at 5 years (Arii et al., 2000; Sala, Llovet, Vilana, Bianchi, Sole, Ayuso & Bru, 2004). Randomized controlled trials (RCT) have also shown that RFA provides better local disease control that could result in an improved survival in RCT (Shiina, Teratani, Obi, Sato, Tateishi, Fujishima & Ishikawa, 2005; Lin, S.M., Lin, C.J., Lin, C.C., Hsu & Chen, 2004).

## **8.2. Palliative Therapies**

### **8.2.1. Systematic Therapies**

With tumour growth, the blood supply becomes progressively arterialized and this characteristic provides the rationale to support arterial obstruction as an effective therapeutic option. Acute arterial obstruction induces ischemic tumour necrosis with a high rate of objective responses.

Transarterial chemoembolization (TACE) is recommended for patients with BCLC stage B, or those with an excellent liver function and multinodular asymptomatic tumours without macroscopic vascular invasion or extra hepatic spread (Llovet & Bruix, 2003).

### **8.2.2. Sorafenib**

Patients who present with more advanced unresectable HCC, or who have either failed TACE, are potential candidates for sorafenib therapy. Sorafenib is a multikinase inhibitor with reported activity against Raf-1, B-Raf, VEGFR2, PDGFR, c-Kit receptors, among others receptor tyrosine kinases and serine threonine kinases (Wilhem, Adnane, Newell, Villanueva, Llovet & Lynch, 2008; Wilhem, Carter, Lynch, Lowinger, Dumas, Smith & Schwartz, 2006).

Evidence of clinical effectiveness from the Sorafenib Hepatocellular Carcinoma Assessment Randomized Protocol (SHARP) Trial, a randomized double blind placebo controlled trial, showed that patients treated with sorafenib experienced significantly prolonged time-to-radiologic progression (5.5 vs. 2.8 months,  $p < 0.001$ ) and improved overall survival (10.7 vs. 7.9 months  $p < 0.001$ ) when compared to placebo (Llovet, Ricci & Mazzaferro, 2008).

The clinical effectiveness and the overall cost-effectiveness of sorafenib therapy in real world settings has yet to be described (Marrero, Kudo & Venook, 2016). Sorafenib is not currently PMB level of care for patients with advanced HCC.

### **8.2.3. Doxorubicin**

In patients with unresectable disease not amenable to or having failed TACE, systemic doxorubicin has been used, mainly in the United States of America (USA), however, its use was based on findings from a large number of single-arm efficacy trials rather than RCTs, and these studies reported a wide variation in response rates (Lencioni, Chen, Dagher & Venook, 2010). Doxorubicin has no proven role, and is currently not recommended as PMB level of care.

## **8.3. Treatment Algorithms**

The choice of treatment for HCC depends mainly on the extent of the disease (Song, Tobe, Inagaki, Kokudo, Hasegawa & Sugawara, 2012). The BCLC staging identifies those with early HCC who may benefit from curative therapies, those at intermediate or advanced disease stage who may benefit from palliative treatments, as well as those at end-stage with a very poor life expectancy.

### **8.3.1 Very Early HCC**

Very early HCC is currently not easy to diagnose confidently prior to treatment. The absence of microvascular invasion in the lesions and dissemination, places these patients in Child-Pugh A stage. The standard treatment for patient with very early HCC is surgical resection. Such patients are thought unlikely to decompensate after resection and are reported to have an excellent 5-year survival rate. Thermal ablation methods provide an alternative treatment option for patients with nodules smaller than 2 cm in diameter. Percutaneous radiofrequency ablation (RFA) is the most widely used standard TA technique. A 5-year survival rate of 68% has been reported with RFA in very-early-stage HCC (Livraghi, Meloni, Di Stasi, Rolle, Solbiati, Tinelli & Rossi, 2008).

### **8.3.2. Early stage HCC**

Early stage disease includes patients with preserved liver function (Child–Pugh A and B) with solitary HCC or up to 3 nodules 3 cm in size. Liver resection, liver transplantation, and percutaneous TA are the various treatment options for such patients, with RFA currently the favored treatment option for patients with early-stage HCC (Bruix & Sherman, 2005). Studies on long-term outcomes of RFA-treated patients have shown consistently high 5-year survival rates in early-stage HCC (Lencioni, Cioni, Crocetti, Franchini, Pina, Lera & Bartolozzi, 2005; Tateishi, Shiina, Teratani, Obi, Sato, Koike, Fujishima, Yoshida & Kawabe, 2005; Choi, Lim, Rhim, Kim, Lee, Paik, Koh, Lee, Choi & Yoo, 2007).

### **8.3.3. Intermediate-stage HCC**

The Barcelona Clinic Liver Cancer (BCLC) algorithm defines intermediate-stage HCC as extensive multifocal disease without vascular invasion in patients with preserved liver function and an absence of cancer-related symptoms. Patients who are intermediate-stage BCLC stage B typically have a good performance status and often have preserved liver function. Transarterial chemoembolization (TACE) is recommended as the standard level of care in such patients, based on improved survival demonstrated in a meta-analysis that compared TACE to the best available supportive care, or to other suboptimal therapies. TACE is associated with overall survival (OS) benefits, although the level of benefit reported varies significantly (Llovet & Bruix, 2003).

### **8.3.4. Advanced stage HCC**

According to the BCLC guidelines, systemic therapy with the multikinase inhibitor sorafenib is considered the standard choice for patients with advanced HCC. However sorafenib is not currently PMB level of care. External beam radiation (EBRT) is an alternative treatment when

the patient is neither suitable for RFA or transplantation (Kwon, 2010; Hawkins, 2006; Andolino, 2011)

**Table 4: Treatment options for HCC**

<b>Therapeutic intervention</b>	<b>Description</b>	<b>Comment</b>
<b>Surgical intervention</b>	Liver resection	Early stage
	Liver transplant	Liver transplant eliminates the possibility of local recurrence at the resection margin; eliminates concerns about the capacity of the post resection liver remnant to provide adequate liver volume.
	Ablation <ul style="list-style-type: none"> <li>- Thermal</li> <li>- chemical ablation</li> </ul>	Ablation is the best treatment option for patients with early stage HCC who are not candidates for resection or transplantation
	Transcatheter arterial chemoembolization (TACE)	For patients who are intermediate-stage BCLC stage B typically have a good performance status and often have preserved liver function
<b>Radiotherapy</b>	Palliative intent	Indicated for pain control
	Curative intent	On motivation on a case by case basis
<b>Treatment exclusions – Not recommended as PMB level of care</b>		
<b>Sorafenib</b>	Sorafenib is not considered PMB level of care.	
<b>Theraspheres</b>	Evidence from a number of studies that patients treated with TheraSphere do not show significantly different overall survival times compared with those treated with conventional transarterial	

	chemoembolisation (TACE) (Salem, Lewandowski, Atassi, Gordon, Gates , Barakat , Sergie , Wong & Thurston , 2005).
<b>Radioembolisation</b>	No randomized controlled trials have been published comparing radioembolisation with other loco-regional or systemic therapies. Clinical trials are needed to establish a competitive efficacy role in these populations.
<b>Intensity modulated radiation therapy (IMRT)</b>	IMRT is not at PMB level of care until evidence on cost-effectiveness as compared to 3d-CRT is available
<b>External beam radiation (EBRT)</b>	
<b>Stereotactic body radiation therapy (SBRT)</b>	There is no phase III data as yet to support SBRT

## 9. Follow up after surgical resection

9.1. Despite optimal treatment, HCC continues to have a high recurrence rate and recurs in 50-80% of patients following resection; with the majority of recurrences developing within 2 years. Careful follow-up in the postoperative period is mandatory. Early recurrence after resection is associated with a dismal prognosis, reducing 5-year survival rates from 70% to 30% (Kim, Reed & Fujita, 2007).

9.2. There are no established guidelines regarding the frequency of imaging procedures in the postoperative period. In general, CT should be performed at 1 month post resection to ensure complete tumor clearance. After this initial scan, serum AFP measurements and repeat imaging studies (e.g., ultrasonography and CT) should be obtained and monitored every 6 to 12 months whilst the MRI can be repeated annually. After 2-3 years, it appears safe to increase the follow-up interval.

**Table 5: Response Evaluation and Follow Up**

		Up to 2 years post diagnosis	3-10 years post diagnosis
		Frequency per year	
<b>Clinical assessment</b>	Primary care practitioner	1	2
	Other specialists	1	1
<b>Laboratory investigations</b>	U&E and Creatinine	1	1
	FBC	1	1

	Liver function tests:	1	1
	Alpha-Fetoprotein	1	1
	Urine dipstix	1	1
	Histopathology	Not routine	
<b>Imaging:</b>	Ulltrasound	2	1
<b>Radiology</b>	CT Abdomen/ Chest	2	1
	CT Brain	Only if clinically indicated	
	MRI Abdomen	1	1

*Please note: Patients with co-morbid diseases impacting on the treatment pathways might require additional consultations, radiology and lab tests.*

***This guideline will be due for update on 31 March 2020***

## References

- Arguedas, M.R., Chen, V.K., Eloubeidi, M.A. & Fallon, M.B. (2003). Screening for hepatocellular carcinoma in patients with hepatitis C cirrhosis: a cost-utility analysis. *American Journal of Gastroenterology*, 98(3):679-90.
- Arii, S., Yamaoka, Y., Futagawa, S., Inoue, K., Kobayashi, K., Kojiro, M., Makuuchi, M., Nakamura, Y., Okita, K. & Yamada, R. (2000). Results of surgical and nonsurgical treatment for small-sized hepatocellular carcinomas: a retrospective and nationwide survey in Japan: The Liver Cancer Study Group of Japan. *Hepatology*, 32:1224–1229.
- Borsh, F.X., Ribes, J., Diaz, M. & Cléries, R. (2004). Primary liver cancer: Worldwide incidence and trends. *Gastroenterology*, 127:5-16.
- Bruix, J. & Sherman, M. (2005). Management of hepatocellular carcinoma. *Hepatology*, 42:1208–1236.
- Bruix, J. & Sherman, M. (2011). American Association for the Study of Liver Disease: management of hepatocellular carcinoma: an update. *Hepatology*, 53:1020-1022.
- Burnett, R.J., Kramvis, A., Dochez, C. & Meheus, A. (2012). An update after 16 years of hepatitis B vaccination in South Africa. *Vaccine*, 30(3):C45-C51.
- Busuttil, R.W., Farmer, D.G., Yersiz, H., Hiatt, J.R., McDiarmid, S.V., Goldstein, L.I., Saab, S., Han, S., Durazo, F., Weaver, M., Cao, C., Chen, T., Lipshutz, G.S., Holt, C., Gordon, S., Gornbein, J., Amersi, F., Ghobrial, R.M. (2005). Analysis of long-term outcomes of 3200 liver transplantations over two decades: a single-center experience. *Annals of Surgery*, 241:905–916.
- Camma, C., Di Marco, V. & Orlando, A. (2005). Treatment of hepatocellular carcinoma in compensated cirrhosis with radiofrequency thermal ablation (RFTA): a prospective study. *Journal of Hepatology*, 42:535–540.
- Chen, C.Y., Li, C.W., Kuo, Y.T., Jaw, T.S., Wu, D.K., Jao, J.C., Hsu, J.S. & Liu, G.C. (2006). Early response of hepatocellular carcinoma to transcatheter arterial chemoembolization: choline levels and MR diffusion constants--initial experience. *Radiology*, 239(2):448–56.
- Chen, M.S., Li, J.Q. & Zheng, Y. (2006). A prospective randomized trial comparing percutaneous local ablative therapy and partial hepatectomy for small hepatocellular carcinoma. *Annals of Surgery*, 243:321–328.
- Choi, D., Lim, H.K., Rhim, H., Kim, Y.S., Lee, W.J., Paik, S.W., Koh, K.C., Lee, J.H., Choi, M.S. & Yoo, B.C. (2007). Percutaneous radiofrequency ablation for early-stage hepatocellular carcinoma as a first-line treatment: long-term results and prognostic factors in a large single-institution series. *European Radiology*, 17:684–692.
- Colombo, M. (2001) Screening for cancer in viral hepatitis. *Clinics in Liver Disease*, 5:109–122.
- Doyle, A. & Sherman, M. (2017). Liver Biopsy for Hepatocellular Carcinoma (HCC): Should this be a Routine? *Current Hepatology Reports*, 16: 46.

Durand, F., Regimbeau, J.M., Belghiti, J., Sauvanet, A., Vilgrain, V., Terris, B., Moutardier, V., Farges, O. & Valla, D. (2001). Assessment of the benefits and risks of percutaneous biopsy before surgical resection of hepatocellular carcinoma. *Journal of Hepatology*, 35(2): 254–258.

Finn, R. S. (2016). The Role of Liver Biopsy in Hepatocellular Carcinoma. *Gastroenterology & Hepatology*, 12(10), 628–630.

Ghanaati, H., Alavian, S.M., Jafarian, A., Ebrahimi Daryani, N., Nassiri-Toosi, M., Jalali, A.H. & Shakiba M. (2012). Imaging and Imaging-Guided Interventions in the Diagnosis and Management of Hepatocellular Carcinoma (HCC)-Review of Evidence. *Iranian Journal of Radiology*, 9(4): 167–177.

Global Burden of Disease Cancer Collaboration. 2016. Global, Regional, and National Cancer Incidence, Mortality, Years of Life Lost, Years Lived With Disability, and Disability-Adjusted Life-years for 32 Cancer Groups, 1990 to 2015. A Systematic Analysis for the Global Burden of Disease Study. *Journal of the American Medical Association- Oncology*, E1-E25.

Grieco, A., Pompili, M., Caminiti, G., Miele, L., Covino, M., Alfei, B., Rapaccini, G.L. & Gasbarrini, G. (2005). Prognostic factors for survival in patients with early-intermediate hepatocellular carcinoma undergoing non-surgical therapy: comparison of Okuda, CLIP, and BCLC staging systems in a single Italian centre. *Gut*, 54(3):411–418.

Huang, G.T., Sheu, J.C., Yang, P.M., Lee, H.S., Wang, T.H. & Chen, D.S. (1996). Ultrasound-guided cutting biopsy for the diagnosis of hepatocellular carcinoma-a study based on 420 patients. *Journal of Hepatology*, 25:334–338.

Hytiroglou, P., Park, Y.N., Krinsky, G. & Theise, N.D. (2007). Hepatic precancerous lesions and small hepatocellular carcinoma. *Gastroenterology Clinics of North America*, 36:867–887.

Ishizawa, T., Hasegawa, K., Aoki, T., Takahashi, M., Inoue, Y., Sano, K., Imamura, H., Sugawara, Y., Kokudo, N. & Makuuchi, M. (2008). Neither multiple tumors nor portal hypertension are surgical contraindications for hepatocellular carcinoma. *Gastroenterology*, 134 (7):1908–1916.

Jeong, S.W., Jang, J.Y., Shim, K.Y., Lee, S.H., Kim, S.G., Cha, S.W., Kim, Y.S., Cho, Y.D., Kim, H.S., Kim, B.S., Kim, K.H. & Kim, J.H. (2013). Practical effect of sorafenib monotherapy on advanced hepatocellular carcinoma and portal vein tumor thrombosis. *Gut Liver*, 7: 696–703.

Johnson, P.J. (2001). The role of serum alpha-fetoprotein estimation in the diagnosis and management of hepatocellular carcinoma. *Clinics in Liver Disease*, 5:145–159.

Llovet, J.M., Ricci, S., Mazzaferro, V., Hilgard, P., Gane, E., Blanc, J.F., Cosme de Oliveira, A., Santoro, A., Raoul, J.C., Forner, A., Schwartz, M., Porta, C., Zeuzem, S., Bolondi, L., Tim F. Greten, Galle, P.R., Seitz, J.F., Borbath, I., Häussinger, D., Giannaris, T., Shan, M., Moscovici, M., Voliotis, D., & Bruix, J. (2008) Sorafenib in advanced hepatocellular carcinoma. *New England Journal of Medicine*, 359 (4):378–390.

Kew, M. (2014). Hepatocellular carcinoma: epidemiology and risk factors. *Journal of Hepatocellular Carcinoma*, 115–125.

Kew, M.C. (2013). Epidemiology of hepatocellular carcinoma in sub-Saharan Africa. *Annals of Hepatology*, 12(2):173-182.

- Kew, M.C., Welschinger, R. & Viana, R. (2008). Occult hepatitis B virus infection in Southern African blacks with hepatocellular carcinoma. *Journal of Gastroenterology Hepatology*, 23(9):1426-1430
- Kobayashi, M., Ikeda, K., Hosaka, T., Sezaki, H., Someya, T., Akuta, N., Suzuki, F., Suzuki, Y., Saitoh, S., Arase, Y. & Kumada, H. (2006). Dysplastic nodules frequently develop into hepatocellular carcinoma in patients with chronic viral hepatitis and cirrhosis. *Cancer*, 106(3):636-647
- Kubota, K., Hisa, N., Nishikawa, T., Fujiwara, Y., Murata, Y., Itoh, S., Yoshida, D. & Yoshida, S. (2001). Evaluation of hepatocellular carcinoma after treatment with transcatheter arterial chemoembolization: comparison of Lipiodol-CT, power Doppler sonography, and dynamic MRI. *Abdominal Imaging*, 26(2):184-90.
- Lau, W.Y. & Lai, E.C. (2007). Salvage surgery following downstaging of unresectable hepatocellular carcinoma: a strategy to increase resectability. *Annals of Surgical Oncology*, 14(12):3301-3309.
- Lencioni, R., Cioni, D., Crocetti, L., Franchini, C., Pina, C.D., Lera, J. & Bartolozzi, C. (2005). Early-stage hepatocellular carcinoma in patients with cirrhosis: long-term results of percutaneous image-guided radiofrequency ablation. *Radiology*, 234:961-967.
- Lin, S.M., Lin, C.J., Lin, C.C., Hsu, C.W. & Chen, Y.C. (2004). Radiofrequency ablation improves prognosis compared with ethanol injection for hepatocellular carcinoma  $\leq$  4 cm. *Gastroenterology*, 127: 1714-1723.
- Livraghi, T., Meloni, F., Di Stasi, M., Rolle, E., Solbiati, L., Tinelli, C. & Rossi, S. (2008). Sustained complete response and complications rates after radiofrequency ablation of very early hepatocellular carcinoma in cirrhosis: Is resection still the treatment of choice? *Hepatology*, 47:82-89.
- Llovet, J.M. & Bruix, J. (2003). Systematic review of randomized trials for unresectable hepatocellular carcinoma: Chemoembolization improves survival. *Hepatology*, 37:429-442
- Llovet, J.M., Di Bisceglie, A.M., Bruix, J., Kramer, B.S., Lencioni, R., Zhu, A.X., Sherman, M., Schwartz, M., Lotze, M., Talwalkar, J. & Gores, G.J. (2008). Panel of Experts in HCC-Design Clinical Trials: Design and endpoints of clinical trials in hepatocellular carcinoma. *Journal of the National Cancer Institute*, 100: 698-711.
- Llovet, J.M., Fuster, J. & Bruix, H. (2004). The Barcelona approach: diagnosis, staging and treatment of hepatocellular carcinoma. *Liver Transplantation*, 10(1):115-120.
- Mancuso, A. (2013). Management of hepatocellular carcinoma: enlightening the gray zones. *World Journal of Hepatology*, 5(6):302-310.
- Marrero, J.A., Kudo, M., Venook, A.P., Ye, S.L., Bronowicki, J.P., Chen, X.P., Dagher, L., Furuse, J., Geschwind, J.H., de Guevara, L.L., Papandreou, C., Takayama, T., Sanyal, A.J., Yoon, S.K., Nakajima, K., Lehr, R., Heldner, S. & Lencioni, R. (2016). Observational registry of sorafenib use in clinical practice across Child-Pugh subgroups: The GIDEON study. *Journal of Hepatology*, 65:1140-1147.
- Park, Y.N. (2011). Update on precursor and early lesions of hepatocellular carcinomas. *Archives of Pathology & Laboratory Medicine*, 135(6):704-715.
- Parkin, D.M. (2006). The global health burden of infection-associated cancers in the year 2002. *International Journal of Cancer*, 118: 3030-3044.

- Parkin, D.M., Bray, F., Ferlay, J. & Pisani, P. (2005). Global cancer statistics, 2002. *CA: A Cancer Journal for Clinicians*, 55:74–108.
- Peng, S.Y., Chen, W.J., Lai, P.L., Jeng, Y.M., Sheu, J.C. & Hsu, H.C. (2004). High alpha-fetoprotein level correlates with high stage, early recurrence and poor prognosis of hepatocellular carcinoma: significance of hepatitis virus infection, age, p53 and beta-catenin mutations. *International Journal of Cancer*, 112(1):44-50.
- Prospective validation of the CLIP score (2000) a new prognostic system for patients with cirrhosis and hepatocellular carcinoma: The Cancer of the Liver Italian Program (CLIP) Investigators. *Hepatology*, 31(4):840.
- Raoul, J. (2008). Natural history of hepatocellular carcinoma and current treatment options. *Seminars in Nuclear Medicine*, 38(2):13–18.
- Lencioni, R., Cioni, D. & Bartolozzi, C. (editor). (2005) *Focal Liver Lesions: Detection, Characterization, Ablation*. Pisa, Italy. Springer Science & Business Media.
- Lencioni, R., Chen, X-P., Dagher, L. & Venook, A.P. (2010) Treatment of Intermediate/Advanced Hepatocellular Carcinoma in the Clinic: How Can Outcomes Be Improved? *The Oncologist*, 15(suppl 4):42–52.
- Roberts, M.S., Angus, D.C., Bryce, C.L., Valenta, Z. & Weissfeld, L. (2004). Survival after liver transplantation in the United States: a disease-specific analysis of the UNOS database. *Liver Transplantation*, 10:886–897.
- Sala, M., Llovet, J.M., Vilana, R., Bianchi, L., Solé, M., Ayuso, C., Brú, C., Bruix, J. & Barcelona Clinic Liver Cancer Group. (2004). Initial response to percutaneous ablation predicts survival in patients with hepatocellular carcinoma. *Hepatology*, 40: 1352–1360.
- Salem, R., Lewandowski, R.J., Atassi, B., Gordon, S.C., Gates, V.L., Barakat, O., Sergie, Z., Wong, C.Y & Thurston, K.G. (2005). Treatment of unresectable hepatocellular carcinoma with use of 90Y microspheres (TheraSphere): safety, tumor response, and survival. *Journal of Vascular and Interventional Radiology*, 16:1627–1639.
- Shiina, S., Teratani, T., Obi, S., Sato, S., Tateishi, R., Fujishima, T., Ishikawa, T., Koike, Y., Yoshida, H., Kawabe, T. & Omata, M. (2005). A randomized controlled trial of radiofrequency ablation with ethanol injection for small hepatocellular carcinoma. *Gastroenterology*, 129:122–130.
- Silva, M.A., Hegab, B., Hyde, C., Guo, B., Buckels, J. A. C. & Mirza, D. F. (2008). Needle track seeding following biopsy of liver lesions in the diagnosis of hepatocellular cancer: a systematic review and meta-analysis. *Gut*, 57(11):1592–1596.
- Song, P., Tobe, R.G., Inagaki, Y., Kokudo, N., Hasegawa, K., Sugawara, Y. & Tang, W. (2012). The management of hepatocellular carcinoma around the world: a comparison of guidelines from 2001 to 2011. *Liver International*, 32:1053–1063.
- Stigliano, L., Marelli, D., Yu, N., Davies, D., Patch, D.W. & Burroughs, A. K. (2007). Seeding following percutaneous diagnostic and therapeutic approaches for hepatocellular carcinoma. What is the risk and the outcome? Seeding risk for percutaneous approach of HCC. *Cancer Treatment Reviews*, 33(5):437–447.

Tateishi, R., Shiina, S., Teratani, T., Obi, S., Sato, S., Koike, Y., Fujishima, T., Yoshida, H., Kawabe, T. (2005). Omata M. Percutaneous radiofrequency ablation for hepatocellular carcinoma: An analysis of 1000 cases. *Cancer*, 103:1201–1209.

The International Consensus Group for Hepatocellular Neoplasia. (2009). Pathologic diagnosis of early hepatocellular carcinoma: a report of the international consensus group for hepatocellular neoplasia. *Hepatology*; 49(2):658–664.

Liu, W., Wang, K., Bao, Q., Sun, Y. & Xing, B. (2016). Hepatic resection provided long-term survival for patients with intermediate and advanced-stage resectable hepatocellular carcinoma. *World Journal of Surgical Oncology*, 14:62.

Wilhelm, S., Carter, C., Lynch, M., Lowinger, T., Dumas, J., Smith, R.A., Schwartz, B., Simantov, R. & Kelley, S. (2006). Discovery and development of sorafenib: a multikinase inhibitor for treating cancer. *Nature Reviews Drug Discovery*, 5: 835–844.

Wilhelm, S.M., Adnane, L., Newell, P., Villanueva, A., Llovet, J.M. & Lynch, M. (2008). Preclinical overview of sorafenib, a multikinase inhibitor that targets both Raf and VEGF and PDGF receptor tyrosine kinase signaling. *Molecular Cancer Therapeutics*, 7: 3129–3140.

Wong, R. & Frenette, C. (2011). Updates in the management of hepatocellular carcinoma. *Gastroenterology Hepatology (NY)*, 7(1):16–24.

World Health Organization Position Paper. (2009). Hepatitis B vaccines. WHO *The Weekly Epidemiological Record*, 84(40):405-420.